



PATIENT

Henry Eilenberg

SPECIES

Canine

BREED

Cavalier

SEX

Male Neutered

AGE

6 years

WEIGHT

27.5lbs

INTERPRETED BY

Maggie Machen
Lamy, DVM
DACVIM (Cardiology)

IMAGING PERFORMED BY

Pamela Harrigan,
RDCS

HOSPITAL NAME

Mass Veterinary Services

REFERRING VET

Dr. Masloski

INVOICE

28381

DATE

1/17/23

PRESENTING CLINICAL SIGNS

History: Recheck echo. History mild chronic valvular disease. Presently, Henry is doing well - eating well with normal activity level. On exam: NSR, grade III/VI murmur with PMI left apical area, PSS, lung fields clear, mm pink, moist, CRT<2. BP: 100-110mmHg.

-Pertinent previous echo findings (1/8/20 Tai Casagrande, DVM, DACVIM-Cardiology): LA 2.2 cm; LA:Ao 1.24; LV 2.88 cm; normal LA size; mild MR; trivial TR (1.75 m/s).

ECHOCARDIOGRAM FINDINGS

2D, m-mode, color flow and Doppler imaging is available.

Left ventricle: The LV diameter is increased with hyperdynamic function. LV wall thicknesses are normal.

Left atrium: The left atrium is moderately dilated.

Mitral valve: The mitral valve is diffusely thickened with mild prolapse into the left atrial lumen. Moderate to severe eccentric mitral regurgitation with a normal velocity.

Aortic valve/Aorta: The aortic valve is normal in morphology and mobility. Normal aortic outflow velocity; laminar flow. No aortic insufficiency.

Right ventricle: Normal right ventricular diameter and morphology indicating no overt evidence of pulmonary arterial hypertension.

Right atrium: Normal RA dimension.

Tricuspid valve: The tricuspid valve appears mildly thickened with trace tricuspid regurgitation. Normal velocity.

Pulmonic valve/Pulmonary artery: The pulmonic valve is normal in morphology and mobility. No pulmonic insufficiency. Normal RVOT velocity; laminar flow.

Pericardium/other: No pericardial or pleural effusion noted. No obvious cardiac masses.

Heart rhythm: ECG reveals a sinus rhythm with an average HR of 115bpm.

2-Dimensional Measurements

Ao diam (cm)	1.9
LA diam (cm)	3.2
LA:Ao (Swe)	1.7
IVS thickness (cm)	0.8
LVID diastole (cm)	4.5
PW thickness (cm)	0.8
LVID systole (cm)	2.3
FS (%)	49

Doppler Measurements

PV Vmax (m/s)	0.6
AoV Vmax (m/s)	1.4
MR Vmax (m/s)	6.3
TR Vmax (m/s)	2.4
TR PG (mmHg)	24

INTERPRETATION OF THE FINDINGS

Chronic degenerative valve disease causing moderate mitral and trace tricuspid regurgitation persists. Compared to the prior study there is evidence of progression in left heart dimensions. Moderate left atrial enlargement indicates there is relatively low risk for imminent complication, however risk for progression to spontaneous congestive heart failure in the future is elevated. No additional issues are identified.

Given LA dilation, Pimobendan is recommended as below. Assessment of progression in the future will help predict long term outcome, however prognosis is guarded at this stage (B2).

RECOMMENDATIONS

- Institute heart muscle support Pimobendan 0.3mg/kg PO q12h.



PATIENT

Henry Eilenberg

SPECIES

Canine

BREED

Cavalier

SEX

Male Neutered

AGE

6 years

WEIGHT

27.5lbs

INTERPRETED BY

Maggie Machen Lamy, DVM
DACVIM (Cardiology)

IMAGING PERFORMED BY

Pamela Harrigan, RDCS

HOSPITAL NAME

Mass Veterinary Services

REFERRING VET

Dr. Masloski

INVOICE

28381

DATE

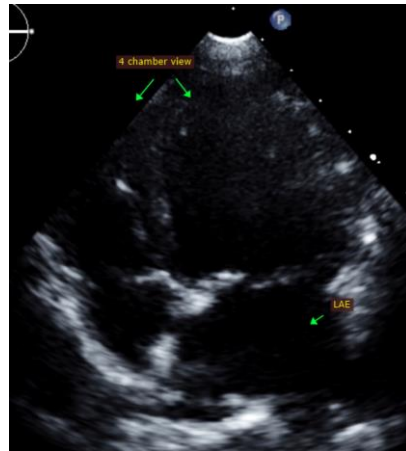
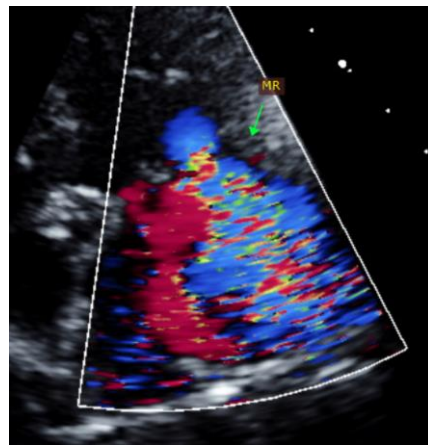
1/17/23

- Omega fatty acid supplementation and mild salt restriction may be of some long-term benefit.
- Once on Pimobendan for 3-5 days, anesthetic risk is considered mild if needed. Cardiac protective drug choices (opioid/benzodiazepine premedication, propofol or alfaxalone induction, isoflurane gas) are recommended. Pre-oxygenate for 5-10 minutes prior to induction. Monitor for arrhythmias, hypotension, and hypoxia both intra and post-operatively and intervene as necessary. Mild IV fluid restriction is recommended to avoid fluid overload. Avoid heart rate stimulating drugs such as atropine unless clinically indicated.
- Monitor for development of a cough, labored breathing, exercise intolerance or collapse episodes.

PLAN

- Recommend conservative monitoring with a recheck echocardiogram in 6 months, sooner if any development of clinical signs.

IMAGES



The information and recommendations provided are based on the images presented by the referring veterinarian. No evaluation can be communicated regarding pathology that was not visible in the image/video clips provided.

Thank you for this referral. This report was generated using transcription software, and minor dictation errors may be present. If the clinical or image interpretation does not parallel your findings or if I can be of any further assistance, please contact me.

Maggie Machen Lamy, DVM
Diplomate of the American College of Veterinary Internal Medicine (Cardiology)
info@sonopath.com

Echocardiogram performed by: Pamela Harrigan, RDCS
Pet Animal Ultrasound Service (4paus.com)